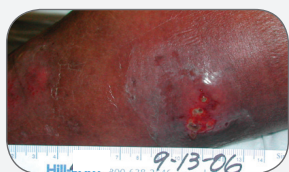


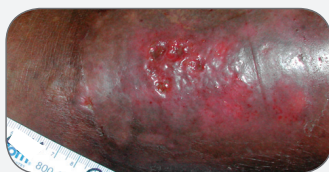
## CASE STUDY

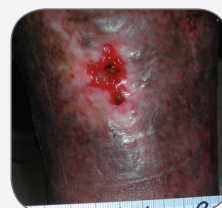# Dramatic Healing of Three Stalled Venous Hypertension Ulcers in a Bariatric Patient Using PolyMem Silver® Dressings Under an Unna's Boot



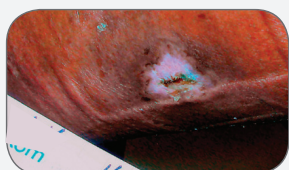
TREATMENT INITIATION



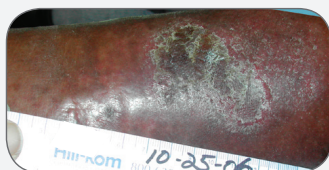TREATMENT INITIATION



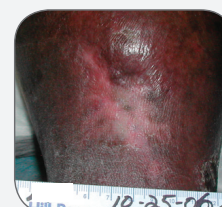TREATMENT INITIATION



CLOSED IN 10 WEEKS



CLOSED IN 6 WEEKS



CLOSED IN 6 WEEKS

# Dramatic Healing of Three Stalled Venous Hypertension Ulcers in a Bariatric Patient Using PolyMem Silver Dressings Under an Unna's Boot

Mariama Hubbard MSN, APNC, Comprehensive Wound Care Center, Jersey Shore University Medical Center, 1945 State Route 33, Neptune, NJ 07754-0397

## PROBLEM

A 58 year old male bariatric (BMI 55) department store worker frequently missed work due to three left lower leg venous hypertension ulcers which were treated with oral antibiotics and twice-daily silver sulfadiazine or an Unna's Boot without improvement. After 7 months of unsuccessful treatment, the primary care physician referred the patient to a wound care nurse. The patient had lower leg hyperpigmentation and dilated veins and the periwound skin was edematous and slightly macerated. His largest ulcer, on his left calf, was 4 cm x 3 cm x 0.5 cm deep and was draining significant quantities of light yellow fluid. He took naproxen sodium for pain, which was 5 during dressing changes and 3 at other times on the 0 – 10 scale.

## RATIONALE

PolyMem dressings are proven to provide significant wound pain relief by inhibiting nociceptor activity at the wound site. Several integral components of PolyMem dressings work together to create an ideal moist environment which concentrates the body's natural healing nutrients by absorbing the watery portion of the wound fluid. In addition to the foam base material, these unique dressings contain a super-absorbent starch, so they are recommended for heavily exudating wounds. PolyMem Silver has additional anti-infective properties. Therefore, PolyMem Silver dressings were initiated.

## METHODOLOGY

The patient was placed on an oral antibiotic for two weeks based upon culture results. After thorough cleansing with saline, a PolyMem Silver dressing was applied with an Unna's Boot over it. Initially a skin barrier spray was used on the periwound skin due to maceration, but this was no longer needed after PolyMem dressing use was established. The wound area was cleansed with normal saline at each dressing change due to the large quantity of exudate. The PolyMem Silver dressing and Unna's boot were changed twice a week.

## RESULTS

After the second dressing change, the patient had pain only during the changing of the dressing on the largest wound. The two smaller ulcers completely closed after six weeks of PolyMem Silver dressing treatment, and the largest ulcer was only 2 cm x 2 cm x 0.1 cm. At 6½ weeks, the patient failed to wear his Unna's Boot for a week and developed new ulcers. But, the two healed ulcers did not break open and the remaining study ulcer did not enlarge; it was fully closed a month later.

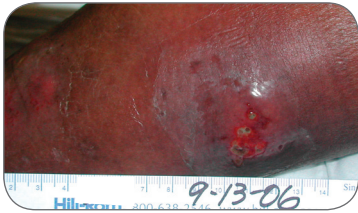## CONCLUSION

After only one week, PolyMem Silver dressing use resulted in new granulation tissue forming in all of these previously stalled venous hypertension wounds. The patient's pain also diminished dramatically. At six weeks, two of the wounds were closed and the final wound was only superficial. It was completely closed 2½ months after beginning treatment with PolyMem Silver dressings.

## OBJECTIVES

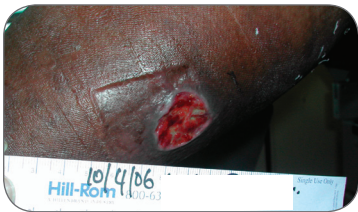1. Evaluate the brisk healing rate achieved using PolyMem Silver dressings on these venous ulcers under compression.
2. Consider the advantages of using PolyMem dressings in terms of the remarkable pain relief patients report.
3. Identify PolyMem as a unique dressing type that promotes appropriate wound moisture conditions, even under compression, by locking extra moisture into a gel form to help prevent maceration while leveraging glycerol to add moisture to dry areas of the wound bed.
4. Note that PolyMem Silver dressings promote cell proliferation while helping inhibit infection.

### Left Posterior Leg Wound



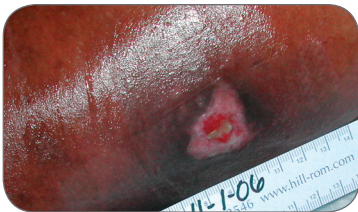**SEPTEMBER 13**

4 cm x 3 cm x 0.5 cm: No healing for 7 months. Began treatment with PolyMem Silver dressings.



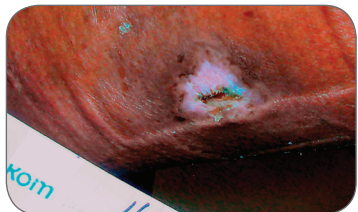
**OCTOBER 4**

3 cm x 3 cm x 0.2 cm: The wound is clearly improving. Mild pain only during dressing changes.



**NOVEMBER 1**

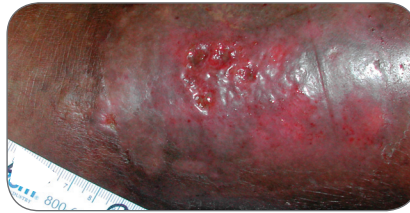1.5 cm x 1.2 cm x 0.1 cm: Drainage is now serous and moderate. Filling in well.



**NOVEMBER 29**

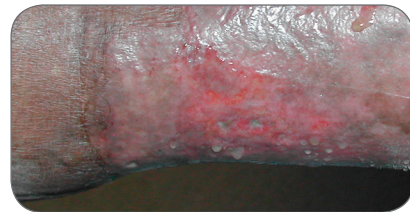
Closed after only 2½ months of using PolyMem Silver dressings. Intact at January follow up.

### Left Lateral Leg Wounds



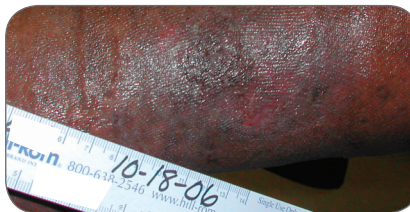**SEPTEMBER 13**

3 cm x 2.5 cm x 0.1 cm: Erythema surrounding 7 month-old wound. Began PolyMem Silver treatment.



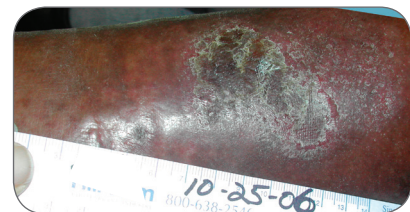**SEPTEMBER 20**

3 cm x 2.5 cm x 0.1 cm: Wound size is unchanged, but periwound area is no longer erythematous and edematous.



**OCTOBER 18**

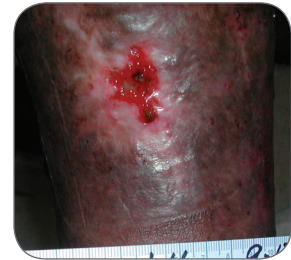3cm x 2 cm x 0.1 cm: No drainage. Wound is superficial and fully granulating.



**OCTOBER 25**

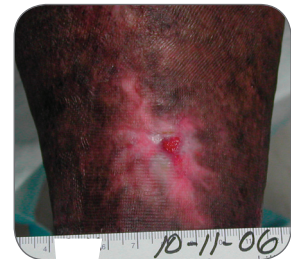Flaked over. Flakes removed November 1 to reveal complete epithelization. Intact skin at January follow up.

### Left Anterior Leg Wound



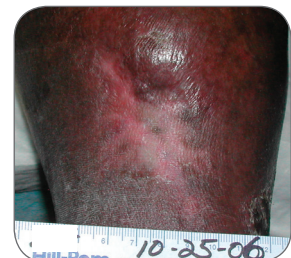**SEPTEMBER 13**

2.5 cm x 2.5 cm x 0.1 cm: Began using PolyMem Silver dressings under the familiar Unna's Boot.



**OCTOBER 11**

1.5 cm x 1.3 cm x 0.1 cm: Dramatic size decrease in just 4 weeks. Cleansed the periwound area only.



**OCTOBER 25**

Fully closed at 6 weeks using PolyMem Silver dressings under Unna's Boot. Remained intact when patient failed to wear compression in November.



## Ferris Mfg. Corp.

16W300 83rd Street | Burr Ridge, Illinois 60527 USA

Toll Free USA: 1.800.POLYMEM (765.9636) | International: +1 630.887.9797

Web site: [www.PolyMem.com](http://www.PolyMem.com)

### BIBLIOGRAPHY:

1. Enoch S, Harding K. Wound bed preparation: The science behind the removal of barriers to healing. *Wounds*. 2003;15(7):213-229.
2. Hess CT. *Wound Care Clinical Guide*. Lippincott Williams & Wilkins. Ambler, PA. 2005; 280-1.
3. Fowler E, Papen JC. Clinical evaluation of a polymeric membrane dressing in the treatment of dermal ulcers. *Ostomy/Wound Manage*. 1991;35:35-38,40-44.
4. Burd A, Kwok CH, Hung SC, Chan HS, Gu H, Lam WK, Huang L. A comparative study of the cytotoxicity of silver-based dressings in monolayer cell, tissue explant, and animal models. *Wound Repair and Regeneration* 2007 15:94-104.
5. Fluhr JW, Gloor M, Lehmann L, Lazzarini S, Distanto F, Berardesca E. Glycerol accelerates recovery of barrier function in vivo. *Acta Derm Venereol*. 1999 79: 418-421.
6. Beitz AJ, Newman A, Kahn AR, Ruggles T, Eikmeier L. A polymeric membrane dressing with antinociceptive properties: analysis with a rodent model of stab wound secondary hyperalgesia. *J Pain*. 2004 Feb;5(1):38-47.

### ORIGINAL POSTER PRESENTED AT\*:

The WOCN Society's 39th Annual Conference. Poster #1261. June 10 - 13, 2007. Salt Lake City, UT USA

\* This version has been modified from the original; it reflects PolyMem branding.

PolyMem, PolyMem Silver, PolyMem Wic, Wic, PolyMem Wic Silver, PolyMem Wic Silver Rope, PolyMem Max, Max, PolyMem Max Silver, Shapes, Shapes by PolyMem, The Shape of Healing, The Pink Dressing, SportsWrap, SportsWrapST, More Healing • Less Pain, interlocking circles design, PolyMem For Sports, Not too Loose...Not too Tight...Just Right!, Ferris and FMC Ferris and design are marks owned by or licensed to Ferris. The marks may be registered or pending in the US Patent and Trademark Office and in other countries. Other marks are the property of their respective owners.