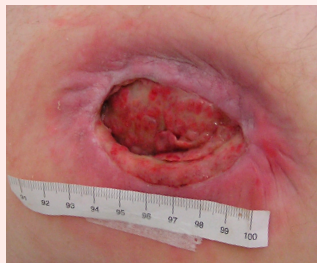

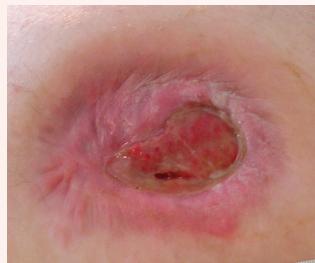# PolyMem®

## CASE STUDY

### Flap Surgery Canceled Through the Use of PolyMem Dressings



**JUNE 13**  
AFTER 13 DAYS OF POLYMEM USE,  
WOUND IS CLEAN.  
3.0 CM OF UNDERMINING IS FILLING IN.



**JULY 29**  
AFTER ONLY 9 WEEKS OF POLYMEM  
USE, UNDERMINING IS RESOLVED.  
DISMISSED TO HOME CARE

# Flap Surgery Canceled Through the Use of PolyMem Dressings

Madeleine Stenius, Assistant Nurse at Rehab Station Stockholm (Sweden)

## INTRODUCTION

A 30-year-old independent man with a 10 – 12 year history of spinal cord injury (tetraplegic: paralyzed legs and body with arm weakness) suffered for 1½ years from a grade IV pressure ulcer on his right hip. This pressure ulcer was 6.5 cm x 4.0 cm with 3.0 cm of undermining on one side. Flap surgery was postponed because the ulcer developed necrosis and an infection.

When he arrived at our rehabilitation center, the man also had nine other pressure ulcers, including a fistula and eight grade III pressure ulcers, with durations ranging from 6 months to 1½ years. The eight grade III pressure ulcers were caused by a huge problem with pain-induced spasticity – a common problem among paralyzed individuals, even with medications. The man had difficulty with transferring to and from his wheelchair and changing positions because of this problem, which particularly caused him to have stiff legs.

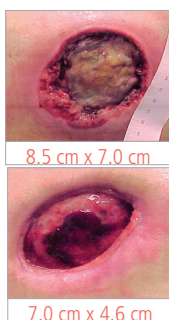
Our mission was to get the grade IV right hip wound infection-free and started healing so the flap surgery would be possible.

## BACKGROUND

This man was first seen at the Rehab Station Stockholm 1½ years prior to this admission when he first developed the sacral and bilateral trochanter and ischial pressure ulcers after a bout of diarrhea. During that time, our facility trialed PolyMem.

These photos show the patient's rapid improvement in only four weeks. Unfortunately, his wounds were not fully closed when the trial ended. Many other modern dressing combinations were attempted after the PolyMem ceased to be available, but all resulted in the wounds stalling or increasing in size.

When he returned to Rehab Station Stockholm because of his infection (see Introduction), he found that PolyMem is now the main dressing we stock. We were able to arrange for him to continue using PolyMem as an outpatient, as well.



## METHODS

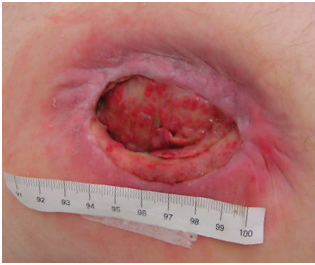PolyMem dressings inhibit the nociceptor activity at the wound site, which often provides significant wound pain relief – or in this case spasticity reduction. The dressings also include components which draw and concentrate healing substances from the body into the wound bed to promote rapid healing, while facilitating autolytic debridement directly by loosening bonds between the slough and the wound. The liquefied slough is absorbed by the dressings, often eliminating the need for wound cleansing at dressing changes. These unique dressings add moisture to dry wounds while absorbing excess fluid, so they are recommended for dry wounds with exposed tendons and bones as well as for heavily exudating wounds.

PolyMem dressings, with PolyMem Wic® cavity filler in the deeper wound cavities, were used on all of the pressure ulcers. The PolyMem and PolyMem Wic were changed 3 times a week, and the patient also had a pressure relief program. It was not necessary to cleanse the wounds routinely at dressing changes.

## RESULTS

All eight of the grade III pressure ulcers closed after only four weeks of treatment with PolyMem dressings. The initial size of the grade IV pressure ulcer on the right hip was 6.5 cm x 4.0 cm with 3.0 cm of undermining on one side. After 2 weeks of using PolyMem dressings, the necrosis and infection had resolved. And, after 5 weeks the undermining was completely filled in and the size of the ulcer was decreased to 6.0 cm x 2.6 cm, so the flap surgery was no longer considered necessary!

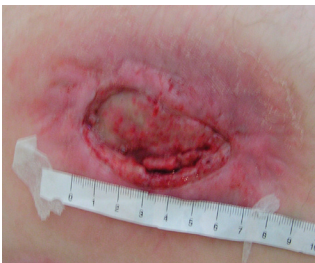After 9 weeks of using PolyMem dressings, the patient was dismissed to continue this wound treatment in his home. The grade IV ulcer was at this point superficial and only 4.6 cm x 2.2 cm. Six months later, despite less supervision for offloading in the out-patient setting and several re-injuries, the grade IV right hip pressure ulcer was completely closed.



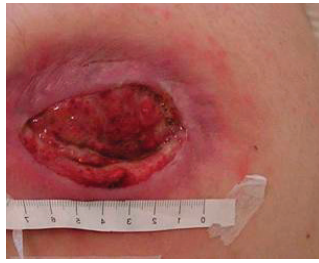**JUNE 13**  
6.5 cm x 4.0 cm. Clean after 13 days of PolyMem. 3.0 cm of undermining is filling in. Was 3-9 o'clock, now 6-9 o'clock.

## OBJECTIVES

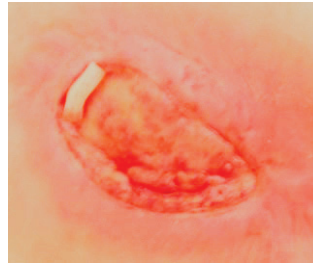1. Review evidence for the use of PolyMem dressings in the treatment of the pain (or spasticity) associated with pressure ulcers.
2. Consider the many advantages associated with PolyMem dressings' ability to passively cleanse the wound bed.
3. Review evidence for the use of PolyMem dressings in the treatment of wounds with both dry areas, such as exposed tendons and bones, and heavily exudating areas, such as the base of a grade IV pressure ulcer.



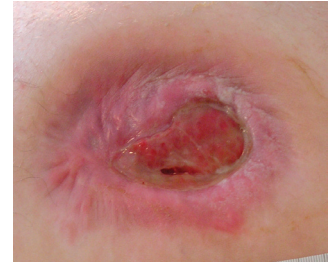**JUNE 23**  
Undermining is filling in rapidly and the infection is gone.



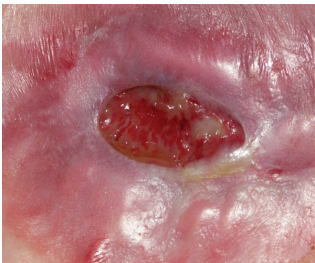**JUNE 30**  
No manual cleansing at dressing changes – the dressing continuously cleanses the wound.



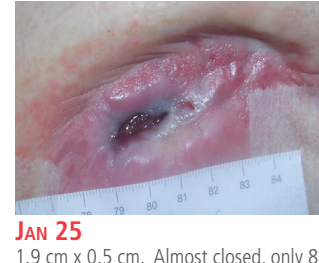**JULY 6**  
6.0 cm x 2.6 cm: Flap surgery canceled. (PolyMem Wic visible in deep cavity, but no more undermining).



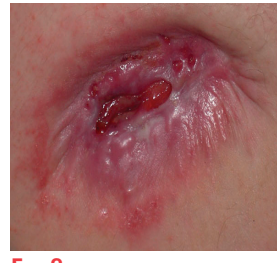
**JULY 29**  
4.6 cm x 2.2 cm with no undermining. Dismissed to home care after 9 weeks of PolyMem use.



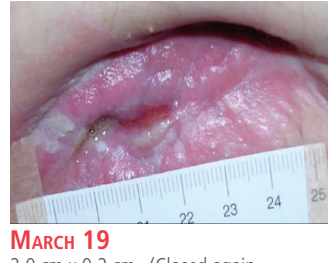**DEC 30**  
2.4 cm x 1.4 cm. Good progress towards wound healing, even at home.



**JAN 25**  
1.9 cm x 0.5 cm. Almost closed, only 8 months after initiating the use of PolyMem.



**FEB 8**  
3.0 cm x 0.8 cm (the wound was closed, but got re-injured on the wheelchair during a transfer).



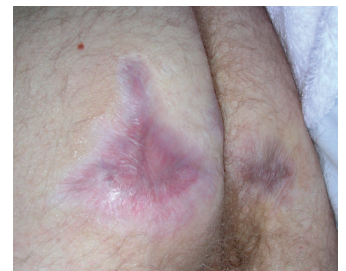**MARCH 19**  
2.0 cm x 0.2 cm. (Closed again completely in April)

## CONCLUSION

After suffering from multiple pressure ulcers for 1½ years, changing to PolyMem dressings resulted in the complete closure of all eight of this patient's grade III pressure ulcers in only 4 weeks. His grade IV right hip pressure ulcer closed in 7 months, saving the patient from plastic surgery.

Being completely wound-free for the first time in over two years has given this young man more energy, as well – he is again working at 75% and sees possibilities instead of just problems with life.

It is quite likely this individual could have been spared at least 1½ years of pain if we could have used PolyMem continuously from the first time he came to our facility.



The other nine ulcers remained closed. The man returned to work (75%) the following year.



## Ferris Mfg. Corp.

5133 Northeast Parkway

Fort Worth, TX 76106 USA

Phone: 1-800-POLYMEM (765-9636), +1 630-887-9797

Email: [info@FerrisPolyMem.com](mailto:info@FerrisPolyMem.com)

Web site: [www.PolyMem.com](http://www.PolyMem.com)

### BIBLIOGRAPHY

1. Bergstrom N, Horn SD, Smout RJ, et al. The national pressure ulcer long-term care study: outcomes of pressure ulcer treatments in long-term care. *J Am Geriatr Soc.* 2005;53(10):1721-1729. 2. Driver VR. Silver dressings in clinical practice. *Ostomy Wound Manage.* 2004 Sep;50(9A Suppl):11S-15S. 3. Fluhr JW, Gloor M, Lehmann L, Lazzerini S, Distante F, Berardesca E. Glycerol accelerates recovery of barrier function in vivo. *Acta Derm Venereol.* 1999;79:418-421. 4. Worley CA. So, what do I put on this wound? Making sense of the wound dressing puzzle: Part II. *Dermatol Nurs.* 2005;17(3):203-205. 5. Hess CT. *Wound Care Clinical Guide.* Lippincott Williams & Wilkins, Ambler, PA. 2005; 275-281. 6. Fowler E, Papen JC. Clinical evaluation of a polymeric membrane dressing in the treatment of dermal ulcers. *Ostomy/Wound Manage.* 1991;35:35-38,40-4. 7. Beitz AJ, Newman A, Kahn AR, Ruggles T, Eikmeier L. A polymeric membrane dressing with antinociceptive properties: analysis with a rodent model of stab wound secondary hyperalgesia. *J Pain.* 2004 Feb;5(1):38-47. 8. Yastrub DJ. Relationship between type of treatment and degree of wound healing among institutionalized geriatric patients with stage II pressure ulcers. *Care Manag J.* 2004 Winter;5(4):213-8.

### ORIGINAL POSTER PRESENTED AT\*:

10<sup>th</sup> Anniversary EPUAP Open Meeting. Poster #20.  
August 30 - September 1, 2007. Oxford, England.

18<sup>th</sup> Conference of the European Wound Management Association. Poster #P36.  
May 14 - 16, 2008. Lisbon, Portugal.

\* This version has been modified from the original; it reflects PolyMem branding.

Unless otherwise indicated, all trademarks identified are owned by or licensed to Ferris. © 2013, Ferris Mfg. Corp., 5133 Northeast Parkway, Fort Worth, TX 76106 USA  
MKL-336, REV-1, 0213