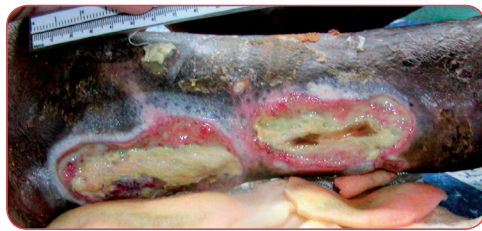


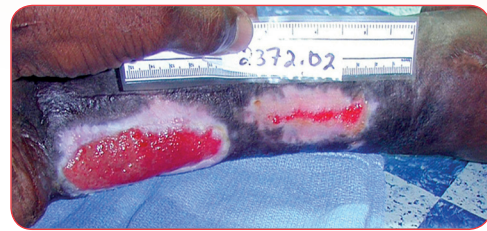
# PolyMem®

## CASE STUDY

### Extensive Tunneling Lower Leg Wounds with Exposed Tendons Closed Quickly Using Various PolyMem Dressings



INITIATION



AFTER ONLY 8 WEEKS OF POLYMEM

# Extensive Tunneling Lower Leg Wounds with Exposed Tendons Closed Quickly Using Various PolyMem Dressings

Linda Benskin, BSN, RN, SRN (Ghana), Peter Bombande, SRN (Ghana), MA, Church of Christ Mission Clinic, PO Box 137, Yendi, Northern Region, GHANA, West Africa

## PROBLEM

A 67-year-old woman with a ten year history of a severe knee deformity which resulted in poor venous return from her right lower leg came to our clinic with extremely painful 9.0 cm x 4.5 cm and 7.5 cm x 4.5 cm foul-smelling abscesses. The wounds were along her Achilles tendon, which was deteriorating with dried brown areas. The patient's only prior treatment was to cover the wounds with cloth to keep out flies. Co-morbidities included intestinal worms and malaria. She refused hospital debridement.

On the third treatment day, we discovered a 0.5 cm in diameter, 5.5 cm long fistula leading from the distal-most end of the superior abscess to an opening near the medial malleolus. The two main wounds connected from this abscess area and several sinus tracts originated there, too.

## MATERIALS AND RATIONALE

The ingredients in PolyMem dressings work synergistically to draw and concentrate the body's natural healing substances into the wound bed to promote rapid healing. These ingredients also facilitate autolytic debridement by loosening bonds between slough and the wound bed. The liquified slough is lifted out of the wound bed and pulled into the dressing to be discarded at dressing changes. Often no manual wound cleansing, which disrupts new tissue growth, or even rinsing, which cools the wound, is needed at dressing changes.

PolyMem Wic® cavity filler is absorbent on all surfaces, while standard PolyMem dressings have an outer semipermeable membrane which facilitates wound moisture optimization. The dressings donate moisture to dry areas of wounds such as exposed tendons while absorbing excess exudate, locking it inside the dressings as a gel. In addition to being non-adherent, these unique dressings inhibit the nociceptor response, so using PolyMem dressings often yields significant relief of wound pain as well as decreased inflammation and edema.

## METHODS

Treatment included oral antimicrobials for the patient's malaria, wound infection and intestinal worms; acetaminophen for pain; prayer; nutritional counseling; and direct wound care. Minimal sharp debridement was followed by wound cleansing with a strong salt water solution. The wounds were initially covered with a PolyMem Max® extra-thick dressing coated with triple-antibiotic ointment.

When the woman returned to the clinic on the third day, the PolyMem Max extra-thick dressing had loosened and absorbed enough adherent yellow slough to reveal some of the fistulas and tunneling wounds and the muscle tissue around the exposed tendons was cleaner. The edges of the two large wounds were already granulating.

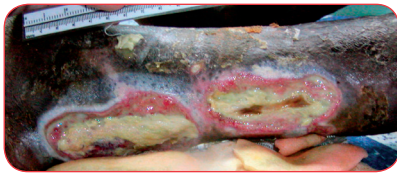Foul exudate was rinsed from the tunnels and fistula with the strong salt solution. PolyMem Wic Silver® cavity filler was at first coated with triple-antibiotic ointment (later this was found to be unnecessary) and was inserted into the sinus tracts and fistulas and the deep muscle contours. The area was completely covered with PolyMem Max extra-thick dressings. The lower leg was then wrapped in strips of bedsheets in an attempt to keep out the dust. Elastic bandages were used for a short time, but they wore out quickly in this hot dusty environment.

## RESULTS

The woman was adamant in her opposition to hospital treatment. No additional sharp debridement was performed. PolyMem Wic Silver cavity filler and PolyMem Max dressings gradually loosened and absorbed the fibrin/slough. Granulation tissue steadily filled in the wound. All tendons were covered and all tunnels were filled within 6 weeks. Various configurations of PolyMem dressings were used to complete wound closure, which occurred after only 4 months of PolyMem dressing use. The woman's pain was controlled so well that she could walk with the aid of a stick throughout the treatment.

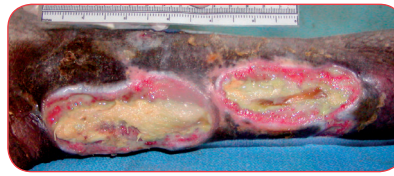
## DISCUSSION and CONCLUSION

PolyMem dressings cleaned and kept these leg wounds with extensive tunnels and exposed tendons infection-free and appropriately moist under very adverse conditions, supporting consistent healing in this patient despite her poor circulation and compromised health. In contrast to negative research reports about other modern silver dressings, healing did not appear to be slowed by cytotoxicity when PolyMem Silver® dressings were used.



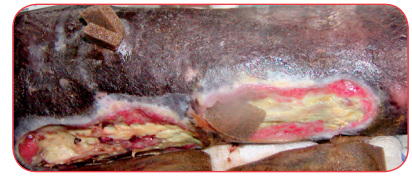**AUG 18**

Two days of treatment with PolyMem Max extra-thick dressing have already softened the fibrin/slough significantly. Further sharp debridement would be risky now: the formerly brown tendons are becoming yellow as they take in moisture and are difficult to distinguish from slough.



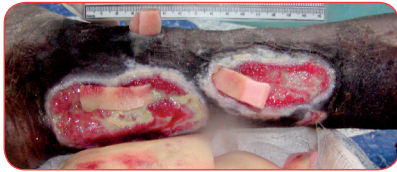
**AUG 21**

Slough continues to melt away much more quickly than would be expected with conventional autolytic debridement (note the edges of the superior wound). The tunnel openings are draining foul brown fluid, but some remain hidden under fibrin/slough.



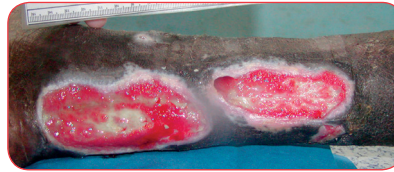
**AUG 27**

The tendons are fully hydrated and are becoming more prominent as the slough/fibrin disappears. The PolyMem Wic Silver cavity filler shows the location of the longest fistula.



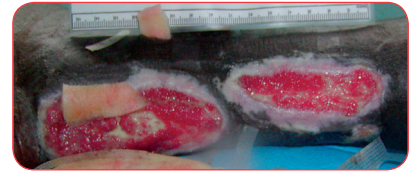
**SEPT 8**

The difference in the wound bed appearance in only ten days is dramatic. As soon as it was clean it began filling in. The tendons are mostly covered. Pink PolyMem Wic cavity filler fills the tunnels and depressions.



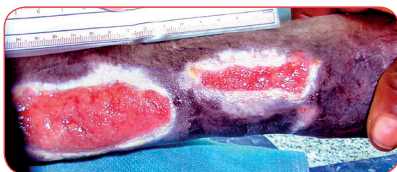
**SEPT 10**

Granulation continues apace. Only a remnant of the long fistula remains. Note: cleansing is still not needed at dressing changes.



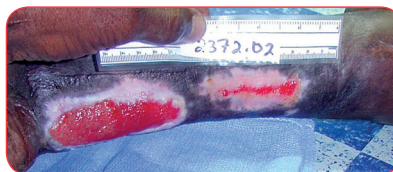
**SEPT 18**

At only one month of treatment with PolyMem dressing, the wound beds are all clean and the tendons are almost covered.



**OCT 4**

Six weeks of using PolyMem dressings. Results are clear; the tendons are all covered and the tunnels are filled.



**OCT 15**

The author traveled, so no further wound photos were taken. However, the chart states the wounds were completely closed at 4 months.

This case study was unsponsored. The clinic receives donated supplies from many sources, including Ferris Mfg. Corp., who contributed to this poster presentation.

## OBJECTIVES

1. Review the evidence for the use of PolyMem dressings and PolyMem Wic Silver cavity filler to maintain infection-free appropriate wound moisture balance and promote rapid healing.
2. Recognize how PolyMem dressings, which continuously cleanse wounds, may avoid the disruption of new growth and cooling which is inherent in other methods of wound cleansing.



## Ferris Mfg. Corp.

16W300 83rd Street | Burr Ridge, Illinois 60527 USA

Toll Free USA: 1.800.POLYMEM (765.9636) | International: +1 630.887.9797

Web site: [www.PolyMem.com](http://www.PolyMem.com)

### BIBLIOGRAPHY:

1. Kahn AR. A Superficial Cutaneous Dressing Inhibits Pain, Inflammation and Swelling In Deep Tissues. Presented at the World Pain Conference, July 15-21, 2000. Pain Medicine 2000 June;1(2):187.
2. Togo T, Alderton JM, Bi GQ and Steinhart RA. The mechanism of facilitated cell membrane resealing. Journal of Cell Science 1999;112(5):719-731.
3. Middleton C. Understanding the physiological effects of unrelieved pain. Nursing Times. September 16, 2003; 99(37):28-31.
4. Markel H. Should Physicians Be Prescribing Prayer? Medscape Pediatrics 2004;6(2).
5. Beitz AJ, Newman A, Kahn AR, Ruggles T, Eikmeier L. A polymeric membrane dressing with antinociceptive properties: analysis with a rodent model of stab wound secondary hyperalgesia. J Pain. 2004 Feb;5(1):38-47.
6. Hess CT. Clinical Guide: Skin and Wound Care. Lippincott Williams & Wilkins. Ambler, PA. 2007;228-231,234-5,343-350.
7. Kim Y, Lee S, Hong S, Lee H, Kim E. The effects of polymem on the wound healing. J Korean Soc Plast Reconstr Surg 1999;109:1165-1172.
8. Burd A, Kwok CH, Hung SC, Chan HS, Gu H, Lam WK, Huang L. A comparative study of the cytotoxicity of silver-based dressings in monolayer cell, tissue explant, and animal models. Wound Repair and Regeneration 2007;15:94-104.

### ORIGINAL POSTER PRESENTED AT\*:

- American Professional Wound Care Association. Poster #20. March 6 -8, 2008. Fort Worth, TX USA.
- 3<sup>rd</sup> Congress of the World Union of Wound Healing Societies. Poster #PF435. June 4 - 8, 2008. Toronto, Ontario Canada.
- 12th Annual Wound Care Congress. Poster #12. September 27 - 28, 2008. Kissimmee, FL USA.
- 23rd Annual Clinical Symposium on Advances in Skin & Wound Care. Poster #41. October 26-29, 2008. Las Vegas, NV USA.

\* This version has been modified from the original; it reflects PolyMem branding.

PolyMem, PolyMem Silver, PolyMem Wic, Wic, PolyMem Wic Silver, PolyMem Wic Silver Rope, PolyMem Max, Max, PolyMem Max Silver, Shapes, Shapes by PolyMem, The Shape of Healing, The Pink Dressing, SportsWrap, SportsWrapST, More Healing • Less Pain, interlocking circles design, PolyMem For Sports, Not too Loose...Not too Tight...Just Right!, Ferris and FMC Ferris and design are marks owned by or licensed to Ferris. The marks may be registered or pending in the US Patent and Trademark Office and in other countries. Other marks are the property of their respective owners.