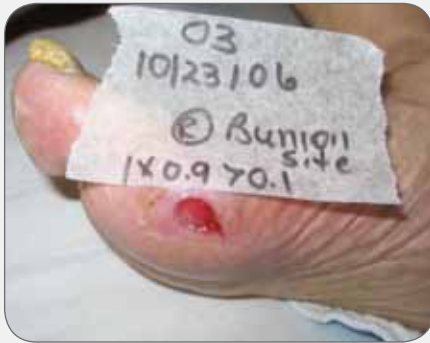
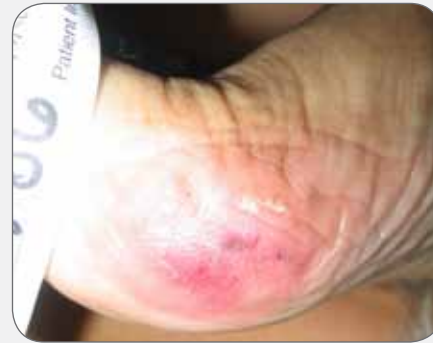
CASE STUDY

Stalled Diabetic Ulcer Closed in Six Weeks Using PolyMem Silver[®] Dressings



INITIATION OF POLYMEM
MANAGEMENT



SIX WEEKS OF POLYMEM
MANAGEMENT

Stalled Diabetic Ulcer Closed in Six Weeks Using PolyMem Silver Dressings

Dasie Wilson, RNC, MPA, ET-CWCN, CCCN, Carlyle Nursing Associates LLC, 8140 River Drive, Morton Grove, IL 60005

PROBLEM

A 68-year-old male long term care resident with controlled diabetes mellitus type 2, severe contractures of the upper and lower extremities, a seizure disorder, peripheral neuropathy, dysphagia, CVA with left hemiparesis, Norton Scale of 6, and bowel and bladder incontinence developed a recurring partial thickness neuropathic ulcer of the right bunion. Treatment for two months consisted of cleansing with normal saline and applying a conventional modern foam dressing every three days and as needed. The foot was elevated and off-loaded. Healing progressed slowly and then stalled with the <0.1 cm deep wound measuring 1.0 cm long x 0.9 cm wide.

RATIONALE

PolyMem dressings contain a gentle cleanser, therefore no manual wound cleansing is usually needed. This dressing feature allows for less disruption of new growth at the wound bed. Dressing changes require less time and application is easy.

Due to the patient's diabetes and co-morbidities, infection was a serious concern. PolyMem Silver dressings have been tested against representative wound pathogens and were found to be effective. Also, since silver in other forms inhibits inflammation, and an extended inflammatory phase is thought to be a factor in stalled wounds, it was hypothesized that silver dressings may "jump-start" stalled wounds.

Recently several conventional modern silver dressings were shown to be severely cytotoxic in vitro and in vivo, but cells in contact with PolyMem Silver dressings proliferated. This further affirms the author's decision to use PolyMem Silver dressings.

METHODOLOGY

After an initial saline flush, a PolyMem Silver dressing was applied. Dressings were reinforced with cloth stretch tape. Per product instructions, no wound cleansing was done during dressing changes, which took place every three days.

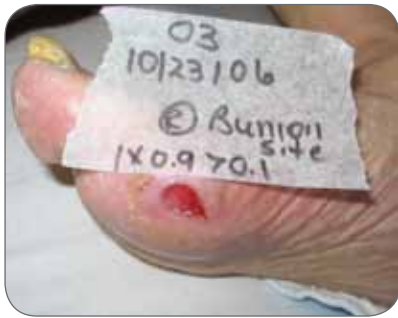RESULTS

When the treatment was changed to PolyMem Silver dressings, the foot ulcer immediately began granulating. Despite co-morbidities and prior setbacks, the wound closed completely in six weeks. Since the dressings are cuttable and wound cleansing supplies were not needed, the total cost of treatment was minimal. The patient has been followed for almost a year; the wound has not recurred.

CONCLUSION

Through the use of PolyMem Silver dressings, this diabetic patient's foot wound rapidly progressed from stalled to granulating to closed.


This case study was unsponsored. Ferris Mfg. Corp. contributed to this poster presentation.



OCTOBER 23

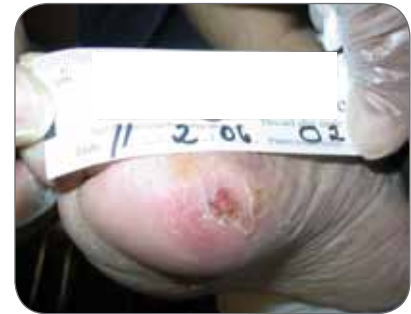1.0 cm x 0.9 cm x <0.1 cm

Initial appearance of the neuropathic wound, which was not improving and contained no granulation tissue despite treatment with standard foam.



OCTOBER 23

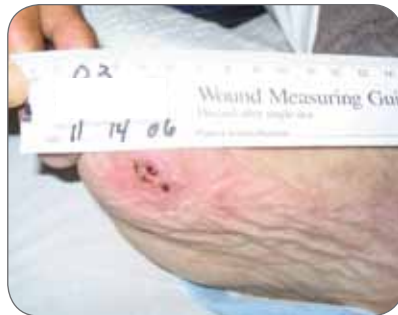The wound was cleansed initially. A piece of PolyMem Silver dressing was applied to the wound. Stretch cloth tape secured the dressing in place.



NOVEMBER 2

0.8 cm x 0.8 cm x <0.1 cm

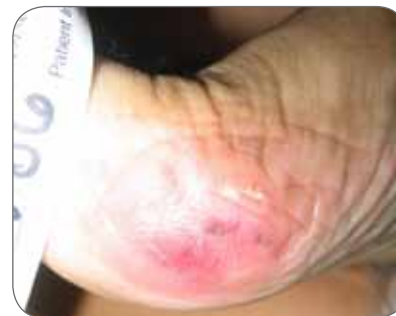No further cleansing was done. By the third dressing change the wound was 20% epithelization tissue and the remaining open area was fully granulating.



NOVEMBER 14

0.3 cm x 0.2 cm x <0.1 cm

Wound healing continued steadily through the use of PolyMem Silver dressings. Wound bed cleansing was not necessary during treatment.



DECEMBER 8

Fully closed.

The neuropathic ulcer completely closed after six weeks of treatment with PolyMem Silver dressings. Dressing changes were quick and easy.

OBJECTIVES

1. Evaluate the clinical performance and the healing rate using PolyMem Silver dressings on a previously stalled diabetic foot ulcer.
2. Consider the advantages of using PolyMem dressings in terms of passive continuous cleansing of the wound bed, which usually eliminates painful and time-consuming wound cleansing during dressing changes.
3. Identify PolyMem dressings as products which promote appropriate wound moisture conditions and cell proliferation while helping inhibit infection.



Ferris Mfg. Corp.

16W300 83rd Street | Burr Ridge, Illinois 60527 USA

Toll Free USA: 1.800.POLYMEM (765.9636) | International: +1 630.887.9797

Web site: www.PolyMem.com

BIBLIOGRAPHY:

1. Fluhr JW, Gloor M, Lehmann L, Lazzarini S, Distante F, Berardesca E. Glycerol accelerates recovery of barrier function in vivo. *Acta Derm Venereol.* 1999 79: 418-421.
2. Ovington LG. The truth about silver. *Ostomy/Wound Management Supplement.* 2004;50(9A):1S-10S.
3. Fowler E, Papen JC. Clinical evaluation of a polymeric membrane dressing in the treatment of dermal ulcers. *Ostomy/Wound Manage.* 1991;35:35-38,40-44.
4. Hess CT. *Clinical Guide: Skin and Wound Care.* Lippincott Williams & Wilkins. Ambler, PA. 2007;228-231,234-5,343-350.
5. Blackman JD, Senseng D, Quinn L, Mazzone T. Clinical evaluation of a semipermeable polymeric membrane dressing for the treatment of chronic diabetic foot ulcers. *Diabetes Care.* 1994;17(4):322-5.
6. Bergstrom N, Horn SD, Smout RJ, et al. The national pressure ulcer long-term care study: outcomes of pressure ulcer treatments in long-term care. *J Am Geriatr Soc.* 2005;53(10):1721-1729.
7. Yastrub DJ. Relationship between type of treatment and degree of wound healing among institutionalized geriatric patients with stage II pressure ulcers. *Care Manag J.* 2004 Winter;5(4):213-8.
8. Burd A, Kwok CH, Hung SC, Chan HS, Gu H, Lam WK, Huang L. A comparative study of the cytotoxicity of silver-based dressings in monolayer cell, tissue explant, and animal models. *Wound Repair and Regeneration* 2007 15:94-104.

ORIGINAL POSTER PRESENTED AT*:

- 17th Conference of the European Wound Management Association. Poster #112. May 2 - 4, 2007. Glasgow, Scotland.
- WOCN Society's 39th Annual Conference. Poster #1219. June 10 - 13, 2007. Salt Lake City, Utah USA.
- 22nd Annual Clinical Symposium on Advances in Skin & Wound Care. Poster #57. October 11 - 14, 2007. Nashville, TN USA.
- Diabetic Foot Global Conference (DFCon). March 13 - 15, 2008. Los Angeles, CA USA.
- 3rd Congress of the World Union of Wound Healing Societies. Poster #PW348. June 4 - 8, 2008. Toronto, Ontario Canada.

* This version has been modified from the original; it reflects PolyMem branding.

PolyMem, PolyMem Silver, PolyMem Wic, Wic, PolyMem Wic Silver, PolyMem Wic Silver Rope, PolyMem Max, Max, PolyMem Max Silver, Shapes, Shapes by PolyMem, The Shape of Healing, The Pink Dressing, SportsWrap, SportsWrapST, More Healing = Less Pain, interlocking circles design, PolyMem For Sports, Not too Loose...Not too Tight...Just Right!, Ferris and FMC Ferris and design are marks owned by or licensed to Ferris. The marks may be registered or pending in the US Patent and Trademark Office and in other countries. Other marks are the property of their respective owners.