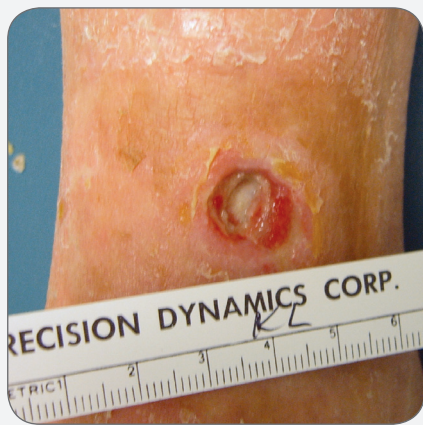


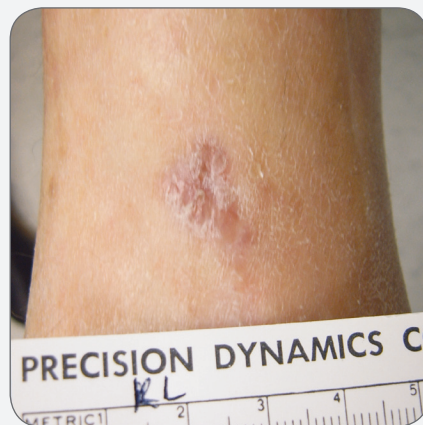
## CASE STUDY

# PolyMem Silver® Dressings Successful in Bringing Quick Closure to a Chronic Venous Ulcer with an Exposed Tendon in a Patient with Arterial Insufficiency



**BEFORE**



**AFTER**

## CASE STUDY

# PolyMem Silver Dressings Successful in Bringing Quick Closure to a Chronic Venous Ulcer with an Exposed Tendon in a Patient with Arterial Insufficiency

June Stamps RN, CWS, Minimal Access Surgery, Inc. 601 W. Maple, Suite 411, Springdale, AR 72764

### PROBLEM

A 47-year-old very tall (5'10") woman with debilitating rheumatoid arthritis and peripheral vascular disease suffered from an infected venous ulcer of her left leg for well over a year. The ulcer was 1.4 cm long, 1 cm wide and 0.4 cm deep with 0.2 cm of undermining under the entire circumference and a partially exposed tendon at the wound base. It was draining large amounts of purulent yellow exudate. The periwound skin was discolored and edematous. Previous treatments included: antibiotic ointment, an enzymatic debrider and wet-to-dry dressings, which all failed to produce improvement. The wound bed remained 100% fibrin/slough. The patient had been taking an oral antibiotic for pseudomonas three weeks prior to coming to the wound clinic. She was also on prednisone, methotrexate, cilostazol and lansoprazole. Her right shoulder and both hips had been replaced due to her arthritis. ABI's were R:0.68, L:0.78. CT angiography of her aorta and iliafemoral artery showed no significant stenosis, but there was calcification of the abdominal aorta. Her wound pain was constant at 5 on a 0 – 10 scale.

### RATIONALE

PolyMem dressings are proven to provide significant wound pain relief by inhibiting nociceptor activity at the wound site. PolyMem dressings also contain ingredients which draw and concentrate healing substances from the body into the wound bed to promote rapid healing while facilitating autolytic debridement by loosening the bonds between the slough and the wound bed. These unique dressings are able to add moisture to dry wounds while absorbing excess wound fluid, so they are recommended for dry wounds including exposed tendons and bones as well as for heavily exudating wounds.

Due to the patient's need for steroids and her serious comorbidities, continued infection was a serious concern. PolyMem Silver dressings have been tested and found to be effective against: *Staphylococcus aureus* (MRSA and Non-MRSA), *Enterococcus faecalis* (VRE), *Klebsiella pneumoniae*, *Pseudomonas aeruginosa* and *Candida albicans*. Recently, several conventional modern silver dressings were shown to be severely cytotoxic in vitro and in vivo, but cells in contact with PolyMem Silver dressings proliferated. This further affirms the author's decision to use PolyMem Silver dressings.

### METHODOLOGY

Initially, the wound was dressed with PolyMem Silver wound dressings, but when the cellulitis resolved, PolyMem dressings were employed instead. Dressings were changed 2 to 3 times/week, with the patient doing some of the dressing changes herself. The patient was instructed to elevate her leg and was given a protein supplement. She continued taking her routine medications. The wound was cleansed with saline at each dressing change per facility protocol. After nine days of treatment, the wound cultured positive for *Staph. aureus*, so the oral antibiotic was renewed.

Compression was not utilized due to the patient's arterial insufficiency.

### OBJECTIVES

1. Formulate a treatment plan for a deep wound with exposed tendon.
2. Discuss problematic issues related to dressing a painful infected wound.
3. Consider the advantages of using PolyMem dressings, rather than systemic medications, to reduce wound pain.
4. Recognize that some of the modern silver dressings currently being marketed have been shown to be toxic to cells, thus delaying wound healing, but cells in contact with PolyMem Silver dressings have been shown to proliferate.

## RESULTS

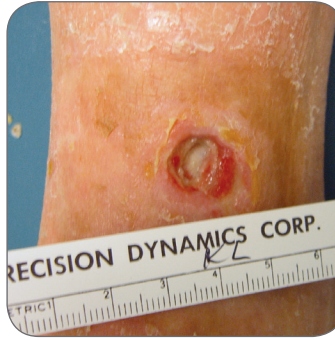Shortly after switching to PolyMem dressings the patient's pain became intermittent at 2 – 3 instead of constant at 5 on the 0 – 10 scale. Four days after the antibiotic was resumed the exudate was moderate, serosanguineous, and without odor. Undermining healed by nine days, and shortly thereafter the main wound bed began clearing of slough and granulating. The tendon was completely covered by the sixth week of treatment and the wound was completely closed at 8 weeks.

## CONCLUSION

The use of PolyMem wound dressings on this patient resulted in reduction of wound pain, a cleaner wound bed and steady healing, including brisk filling in of the undermining and complete coverage over the exposed tendon. Despite the patient's steroid intake and arterial insufficiency, this tenacious wound that had afflicted her for well over a year closed in only 8 weeks. Further, the patient realized a significant cost-savings associated with fewer weekly dressing changes and her ability to do some of the changes herself.

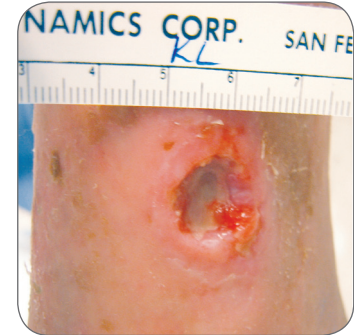
---

This case study was unsponsored. Ferris Mfg. Corp. contributed to the poster presentation.



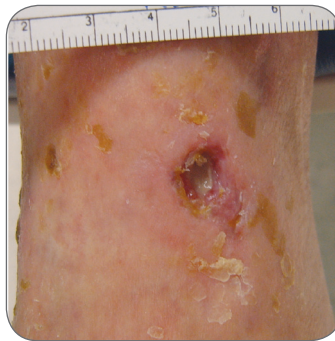
**September 26**

1.4 cm x 1 cm x 0.4 cm  
Constant pain @ 5. Wound base is an exposed tendon. PolyMem Silver dressings initiated.



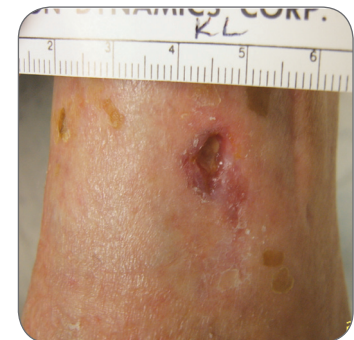**October 9**

1.2 cm x 1.1 cm x 0.4 cm  
Granulation tissue is beginning to form over the exposed tendon. Pain is now intermittent @ 2 – 3.



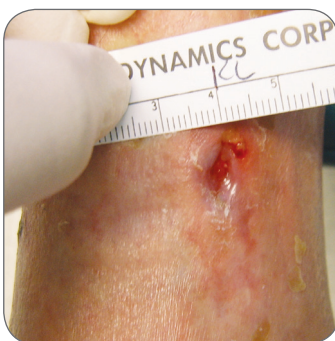**October 26**

0.8 cm x 0.7 cm x 0.3 cm  
Considerable granulation tissue over tendon. Pain remains intermittent @ 2 – 3.



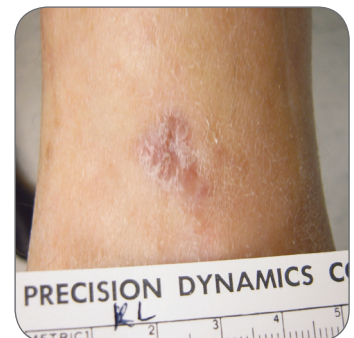
**November 6**

0.8 cm x 0.2 cm x 0.2 cm  
Tendon is completely covered. Pain remains only intermittent @ 2 – 3.



**November 13**

0.2 cm x 0.2 cm, almost no depth. Filling in very well. Pain during treatment only. Almost closed.



**December 12**

The wound was completely closed on Nov 21. This follow-up photo was taken three weeks later.



**Ferris Mfg. Corp.**

5133 Northeast Parkway • Fort Worth, TX 76106 USA

Toll-Free USA: 1.800.POLYMEM (765.9636) • International: +1 817.900.1301

[www.polymem.com](http://www.polymem.com)

**BIBLIOGRAPHY:**

1. Fluhr JW, Gloor M, Lehmann L, Lazzerini S, Distante F, Berardesca E. Glycerol accelerates recovery of barrier function in vivo. *Acta Derm Venereol.* 1999;79:418-421.
2. Ovington LG. The truth about silver. *Ostomy/Wound Management Supplement.* 2004;50(9A):15-10S.
3. Fowler E, Papen JC. Clinical evaluation of a polymeric membrane dressing in the treatment of dermal ulcers. *Ostomy/Wound Manage.* 1991;35:35-38,40-44.
4. Hess CT. *Wound Care Clinical Guide.* Lippincott Williams & Wilkins. Ambler, PA. 2005; 275-276.
5. Clay CS, Chen, WYJ. Wound pain: the need for a more understanding approach. *Journal of Wound Care.* 2005;14:4,181-184.
6. Beitz AJ, Newman A, Kahn AR, Ruggles T, Eikmeier L. A polymeric membrane dressing with antinociceptive properties: analysis with a rodent model of stab wound secondary hyperalgesia. *J Pain.* 2004 Feb;5(1):38-47.
7. Foresman PA, Etheridge CA, Rodeheaver G. A wound dressing evaluation of partial-thickness rat wounds. *SAWC Health Management Pub.* 1991; Annual Meeting Power Point Presentation.
8. Burd A, Kwok CH, Hung SC, Chan HS, Gu H, Lam WK, Huang L. A comparative study of the cytotoxicity of silver-based dressings in monolayer cell, tissue explant, and animal models. *Wound Repair and Regeneration* 2007 15:94-104.

**ORIGINAL POSTER PRESENTED AT\*:**

- The WOCN Society's 39th Annual Conference. Poster #1237. June 10 - 13, 2007. Salt Lake City, UT USA.
- 20th Annual Symposium on Advanced Wound Care (SAWC). Poster #330. April 28 - May 1, 2007. Tampa, FL USA.
- 17th Conference of the European Wound Management Association. Poster #120. May 2 - 4, 2007. Glasgow, Scotland.

\* This version has been modified from the original; it reflects PolyMem branding.

PolyMem, PolyMem Silver, PolyMem Wic, Wic, PolyMem Wic Silver, PolyMem Wic Silver Rope, PolyMem Max, Max, PolyMem Max Silver, Shapes, Shapes by PolyMem, The Shape of Healing, The Pink Dressing, SportsWrap, SportsWrapST, More Healing - Less Pain, interlocking circles design, PolyMem For Sports, Not too Loose...Not too Tight...Just Right!, Ferris and FMC Ferris and design are marks owned by or licensed to Ferris. The marks may be registered or pending in the US Patent and Trademark Office and in other countries. Other marks are the property of their respective owners.