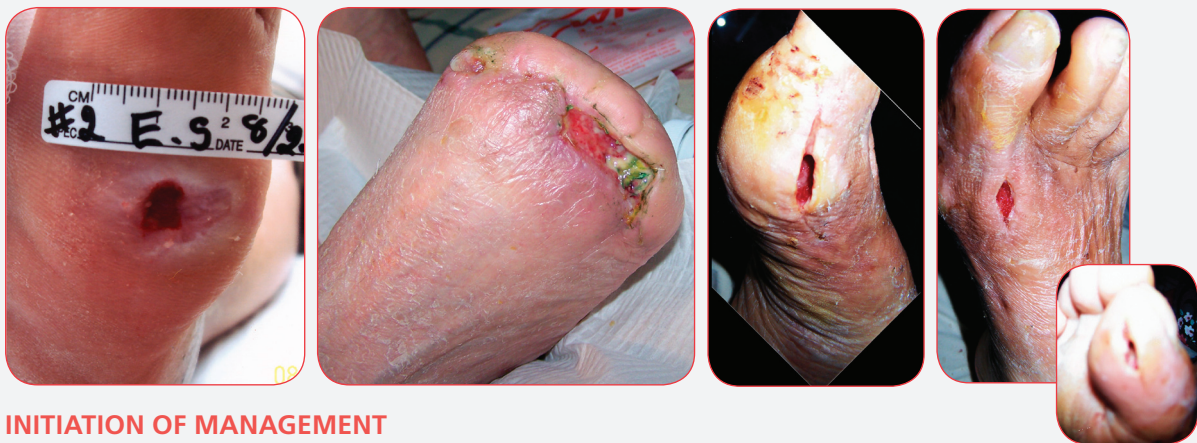



## CASE STUDY

# Stalled Infected Diabetic Foot Wounds Respond Rapidly to Various PolyMem Dressing Types



INITIATION OF MANAGEMENT

## CASE STUDY

# Stalled Infected Diabetic Foot Wounds Respond Rapidly to Various PolyMem Dressing Types

Patricia Seemann, BSN, RN, WCC, Care America Home Health, 531 Wekiva Commons Circle, Apopka, FL 32712-3645

### PROBLEM

Infected diabetic foot wound patients are often referred to this WCC nurse after months of previous treatments, including appropriate antibiotics, result in no decrease in wound size. This case series demonstrates a consistently effective treatment method for such patients.

Three infected foot wounds in diabetic patients are included as examples. A plantar wound developed recurrent MRSA infections. A transmetatarsal amputation site was necrotic and also MRSA infected. An infected bunionectomy site was being considered for a \$3000/month treatment which the insurance company was questioning. All three patients needed a cost-effective treatment method that could achieve quick wound closure.

### METHODOLOGY

After an initial saline flush, deep wound areas were lightly filled with PolyMem Wic® or PolyMem Wic Silver® cavity filler, then covered with standard PolyMem or PolyMem Silver dressings. PolyMem dressings continuously cleanse, fill, moisten and absorb the entire time they are in contact with the wound. They can do this because they are PolyMem: they contain a surfactant, super-absorbent starch and glycerol, which work synergistically to draw and concentrate the body's natural healing substances into the wound bed to promote rapid healing. They facilitate autolytic debridement by loosening bonds between slough and the wound bed. Liquefied slough is absorbed by the dressings. This often eliminates the need for disruptive wound cleansing or even cooling rinsing during dressing changes.

PolyMem Silver dressings have antimicrobial properties. Silver versions of the PolyMem products were used initially and intermittently to minimize bioburden. Dressings were changed when saturated: generally two-to-three times per week. The necrotic transmetatarsal amputation site was flushed with saline at dressing changes for the first two weeks. No other manual wound cleansing was needed.

### RESULTS

The plantar wound closed in just over five weeks. The necrotic transmetatarsal site closed in only six weeks, and the bunionectomy site took just over three weeks to close. Since PolyMem dressings are cuttable and cleansing is seldom necessary at dressing changes, the patients used very few PolyMem dressings in all and were able to do many of the dressing changes themselves.

### CONCLUSION

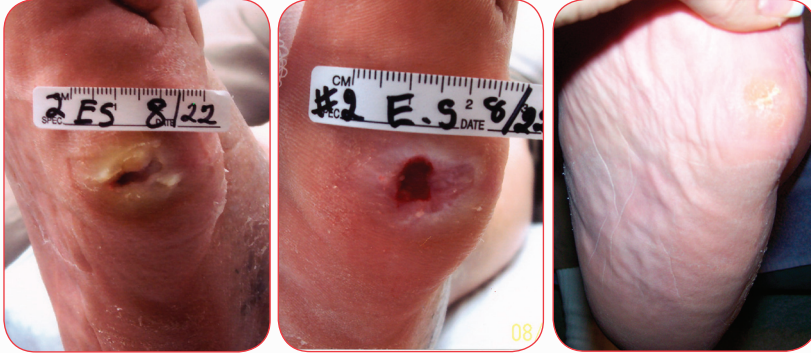
Switching to PolyMem Wic cavity filler and PolyMem dressings led to a complete turnaround for these discouraging, stalled wounds in only one week with minimal clinician intervention, completely closing them in six weeks or less. Wound management with PolyMem Wic and PolyMem Wic Silver cavity fillers, along with PolyMem dressings was extremely cost-effective.

### OBJECTIVES

1. Recognize using PolyMem dressings as an innovation that can lead to quick healing with minimal clinician intervention, resulting in high patient satisfaction and very low overall treatment costs.
2. Note that in addition to the continuous cleansing benefits of the standard pink PolyMem dressings, PolyMem Silver is directly effective against MRSA and other common wound organisms.

This case series was unsponsored. Ferris Mfg. Corp. contributed to this poster presentation.

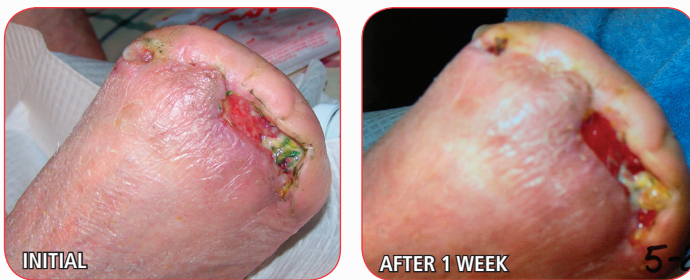### PATIENT 1:



A diabetic with a 14-month-old plantar wound was referred to a wound center, where the callous was removed. Antibiotics for a MRSA infection led to aplastic anemia, and the wound was not healing, so after 6 more weeks the wound nurse was consulted.

The first two photos are from the wound center, showing the initial presentation before and after callous removal. The patient's condition deteriorated until he was switched to PolyMem Wic Silver cavity filler. No wound cleansing was performed at dressing changes. Silver and pink PolyMem dressings were alternated. The wound closed in only 5 weeks.

### PATIENT 2:

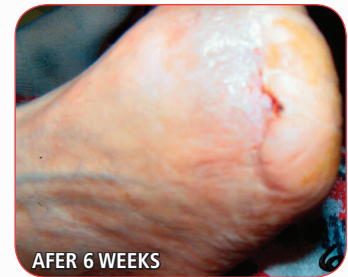
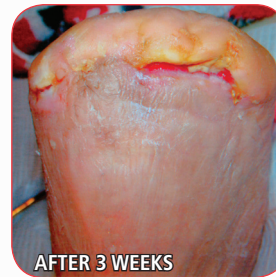
A retired diabetic man was given daily wound treatment with an enzymatic debriding ointment covered with wet gauze then a dry conforming wrap by a home health RN, and he went in weekly for sharp debridement by the podiatrist. But, his 2.0 cm x 4.0 cm x 0.3 cm MRSA infected necrotic transmetatarsal amputation site wound did not change in size. After seven weeks, he complained to his doctor, who referred him to the wound nurse.

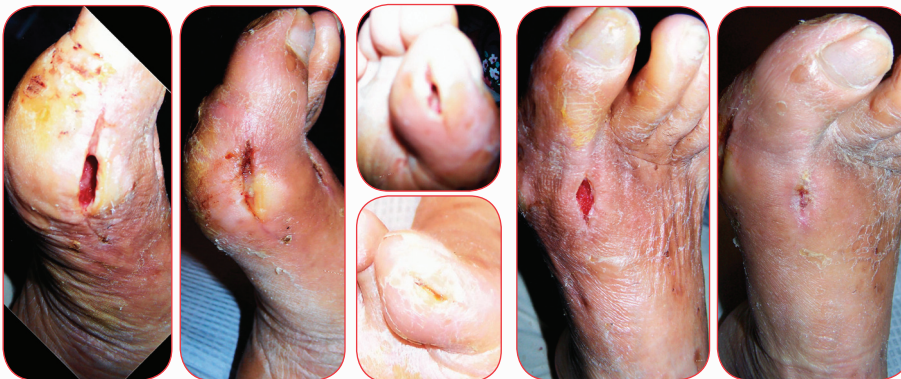At first, the wound was flushed with saline at dressing changes, but after two weeks even this amount of wound cleansing was no longer needed.

Pink PolyMem Wic cavity filler was used in the deep areas, and the entire wound area was covered with a standard pink PolyMem dressing. Protective ointment was applied to the periwound area and the entire forefoot was wrapped in Conform™ gauze.

Dressings were changed daily for the first week, then three times weekly. PolyMem Wic Silver was used during the second week to decrease bioburden. Initially the wound bed was 50% avascular and 50% fibrin with no granulation tissue and rolled discolored margins. After only one week, the edges were flat and the wound bed was 70% granulated with only 30% fibrin and no avascular tissue. The third and fourth weeks steri-strips were used to help pull the wound together. By the fourth week the wound was so shallow that the PolyMem Wic cavity filler was no longer needed – standard PolyMem was used alone. The wound fully closed in only six weeks.



### PATIENT 3:



PolyMem Wic Silver cavity filler in the great toe and bunion sites, and PolyMem Silver on the top of the foot were secured with dry sterile gauze and Conform wraps and changed twice weekly. The top of the foot closed in 10 days; the great toe area closed in 12 days; the bunion area was granulated to the surface at 16 days (pictured) and fully closed at 23 days. IV antibiotics were continued for 3 more weeks.

Total:

- 1 - 4" x 4" PolyMem Silver dressing,
- 1 - 4" x 4" standard pink PolyMem dressing,
- 1 - 3" x 3" PolyMem Wic Silver cavity filler,
- 8 Conform wraps used, and
- 11 nursing visits (including IV follow up).

A diabetic man with chronic renal failure and peripheral arterial disease had three infected deep wounds post-bunionectomy. Conventional modern wound care and IV antibiotics were ineffective, and insurance refused to cover negative pressure wound therapy, so the wound nurse was consulted.



**Ferris Mfg. Corp.**

5133 Northeast Parkway | Fort Worth, TX 76106 USA

Toll Free USA: 1.800.POLYMEM (765.9636) | International: +1 817.900.1301

www.polymem.com

#### BIBLIOGRAPHY:

1. Enoch S, Harding K. Wound bed preparation: The science behind the removal of barriers to healing. *Wounds*. 2003;15(7):213-229.
2. Cutting KF, White RJ. Criteria for identifying wound infection: Revisited. *Ostomy/Wound Management*, 2005;51(1): 28-34.
3. Hess CT. *Clinical Guide: Skin and Wound Care*. Lippincott Williams & Wilkins. Ambler, PA. 2007;228-231,234-5,343-350.
4. Fowler E, Papen JC. Clinical evaluation of a polymeric membrane dressing in the treatment of dermal ulcers. *Ostomy/Wound Manage*. 1991;35:35-38,40-44.
5. Blackman JD, Senseng D, Quinn L, Mazzone T. Clinical evaluation of a semipermeable polymeric membrane dressing for the treatment of chronic diabetic foot ulcers. *Diabetes Care*. 1994;17(4):322-5.
6. Driver VR. Silver dressings in clinical practice. *Ostomy Wound Manage*. 2004 Sept;50(9A Suppl):11S-15S.
7. Burd A, Kwok CH, Hung SC, Chan HS, Gu H, Lam WK, Huang L. A comparative study of the cytotoxicity of silver-based dressings in monolayer cell, tissue explant, and animal models. *Wound Repair and Regeneration* 2007;15:94-104.
8. Kim Y, Lee S, Hong S, Lee H, Kim E. The effects of polymem on the wound healing. *J Korean Soc Plast Reconstr Surg* 1999;109:1165-1172.
9. Kahn AR. A Superficial Cutaneous Dressing Inhibits Pain, Inflammation and Swelling In Deep Tissues. Presented at the World Pain Conference, July 15-21,2000. *Pain Medicine* 2000 June;1(2):187.
10. Wilson D. Stalled diabetic ulcer closed in six weeks using silver polymeric membrane dressings. Presented at Wound Ostomy Continence Nursing (WOCN) Society 39th Annual Conference. Poster #1219, June 10 – 13, 2007. Salt Lake City, UT USA.

#### ORIGINAL POSTER PRESENTED AT\*:

Diabetic Foot Global Conference (DFCon). March 13 - 15, 2008. Los Angeles, CA USA.

12th Annual Wound Care Congress · Poster #21. September 27 - 28, 2008. Orlando, FL USA.

22nd Annual Symposium on Advanced Wound Care & WHS Meeting. Poster #CS079. April 26 - 29, 2009. Dallas, TX USA.

\* This version has been modified from the original; it reflects PolyMem branding.

PolyMem, PolyMem Silver, PolyMem Wic, Wic, PolyMem Wic Silver, PolyMem Wic Silver Rope, PolyMem Max, Max, PolyMem Max Silver, Shapes, Shapes by PolyMem, The Shape of Healing, The Pink Dressing, SportsWrap, SportsWrapST, More Healing • Less Pain, interlocking circles design, PolyMem For Sports, Not too Loose...Not too Tight...Just Right!, Ferris and FMC Ferris and design are marks owned by or licensed to Ferris. The marks may be registered or pending in the US Patent and Trademark Office and in other countries. Other marks are the property of their respective owners.

© 2013 Ferris Mfg. Corp.

MKL-406,REV-2,0513