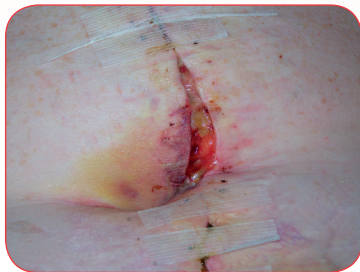

PolyMem[®]

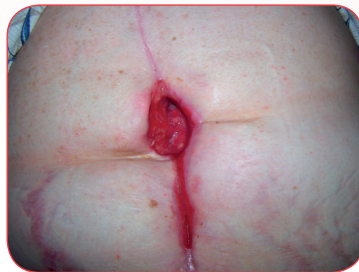CASE STUDY

PolyMem Wic[®] and PolyMem Wic Silver[®] Cavity Filler Dramatically Enhances Quality of Life for Patient with Dehisced Abdominal Wound



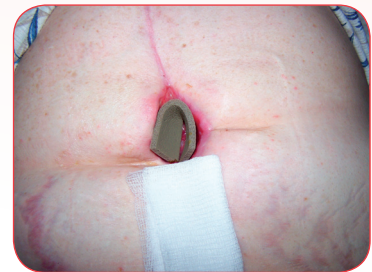10 AUG

Aortic aneurysm surgical site continuing to dehisce.



15 SEPT

37 days of management with PolyMem Wic cavity filler. Significant reduction in wound size, bioburden, wound-related pain, and elimination of need to cleanse wound at dressing changes.



PolyMem Wic and PolyMem Wic Silver Cavity Filler Dramatically Enhances Quality of Life for Patient with Dehisced Abdominal Wound

PATRICIA SEEMANN, BSN, RN, WCC, Care America Home Health, 531 Wekiva Commons Circle, Apopka, FL 32712-3645

PROBLEM

A 63-year-old hypertensive woman with a midline abdominal incisional wound post-aneurysm repair suffered a dehiscence within 13 days of staple removal. The patient was seen in the emergency room, where the 17.0 cm x 6.0 cm x 5.0 cm wound was surgically debrided and she was prescribed wet-to-dry normal saline gauze dressings to be changed twice daily. Wound pain was 10 on the 0 – 10 scale during treatment and intermittent in between. When the wound nurse was consulted three days later, the wound remained bloody and avascular with large amounts of drainage.

RATIONALE

PolyMem dressings can help reduce wound pain not only during dressing changes, but also while the dressing is in place, by inhibiting nociceptor activity at the wound site. Glycerol in the dressing prevents sticking. Starch co-polymers give the dressings superior absorption by locking exudate in the dressing in gel form. The dressings contain a gentle cleanser, so after the initial treatment no manual wound cleansing is usually needed, allowing for less disruption and cooling of the new growth at the wound bed and very quick and easy dressing changes. The ingredients in PolyMem dressings work together to draw and concentrate healing substances from the body into the wound bed to promote rapid healing. PolyMem dressings are available in a cavity filler form, without the semipermeable backing, so that all of the surfaces can absorb wound fluid. Therefore, PolyMem Wic cavity filler was initiated.

METHODOLOGY

The wound bed was flushed with saline initially. PolyMem Wic cavity filler was placed into the large wound and topped with an abdominal pad secured with tape. Dressings were changed every-other-day with no wound cleansing or rinsing. As healing progressed, dressing change frequency was further decreased to 2 or 3 times per week. PolyMem Wic Silver cavity filler replaced the pink PolyMem Wic cavity filler once a week to keep bioburden under control.

RESULTS

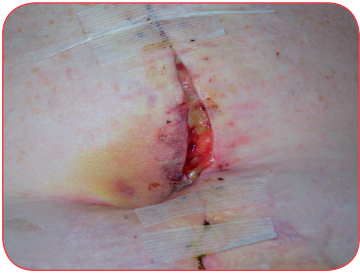
The patient's pain during dressing changes immediately dropped to 0 – 1 with no pain at all between dressing changes. Nine days after initiating PolyMem Wic cavity filler, the wound was fully granulating. The wound is closing steadily and is now only 1.5 cm x 1.0 cm x 0.5 cm with scant serosanguineous drainage. The wound bed remained clean and, because traumatic rinsing or cleansing was not needed, it bled far less.

CONCLUSION

Use of PolyMem Wic and PolyMem Wic Silver cavity fillers dramatically diminished the patient's pain and promoted brisk granulation of her wound. Painful wound cleansing was completely eliminated and the dressings only had to be changed 2 – 4 times per week instead of 14 times per week. The wound closed steadily without infection or other complications. All of these improvements saved both material costs and clinician time and greatly enhanced the patient's quality of life.

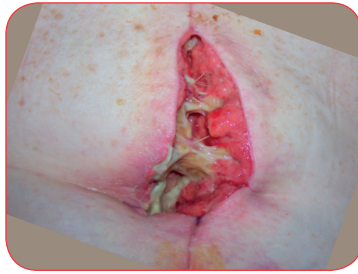
OBJECTIVES

1. Recognize that the built-in continuous cleansing system provided by PolyMem dressings leads to quick, easy, atraumatic dressing changes and helps to maintain a warm undisturbed healing environment in the wound bed.
2. Explore how much a patient's quality of life can be improved by dramatically decreasing the frequency and painfulness of dressings changes.
3. Consider the psychological encouragement gained by this patient when PolyMem dressing use resulted in an immediate improvement in wound bed appearance.



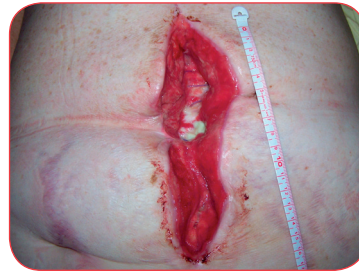10 AUG

The aortic aneurysm surgical site continues to dehisce. With the switch to PolyMem Wic cavity filler under an ABD, dressing change pain, which was 10, decreased to 0 – 1.



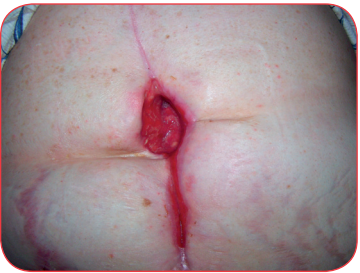
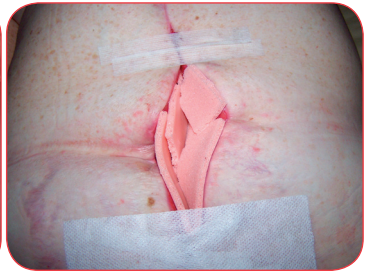
19 AUG

The steri-strips are detaching, revealing sloughy subcutaneous tissue. But, granulation tissue is already forming where the cavity filler has made contact with the wound surface.



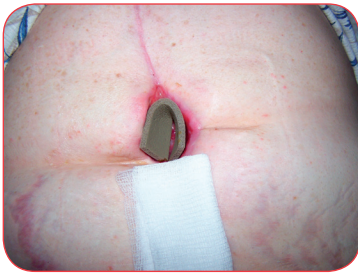4 SEPT

The wound is now fully dehisced: 17.0 cm x 6.0 cm x 5.0 cm. PolyMem Wic cavity filler keeps the aorta and surrounding tissue clean and appropriately moist without cleansing or even rinsing during dressing changes. Clean, fully granulated wound edges are pulled together with steri-strips to hasten wound closure.

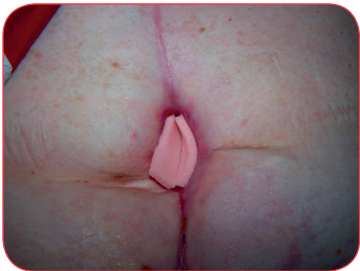

15 SEPT

In just 11 more days (5 dressing changes), the cavity size has decreased to only 4.0 cm x 2.75 cm x 2.0 cm deep. The wound bed remains clean. PolyMem Wic Silver cavity filler is still used every other week to decrease bioburden as a precautionary measure against wound infection in this at-risk patient.

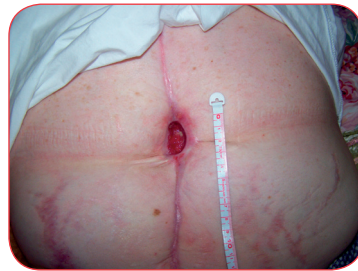

This case study was unsponsored. Ferris Mfg. Corp. contributed to the poster presentation.



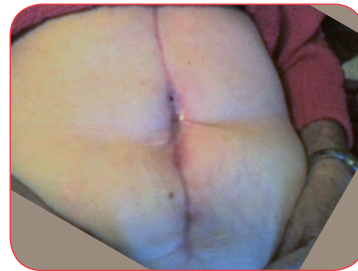
29 SEPT

The wound continues to close. PolyMem dressings are non-adherent, so dressing changes are atraumatic and cause no discomfort at all to the patient.



18 OCT

PolyMem Wic cavity filler is now replaced only twice a week. A standard 4 x 4 covers the wound area. (This treatment was continued to complete closure.)



15 NOV

The 17.0 cm x 6.0 cm x 5.0 cm dehisced abdominal wound closed completely in just over three months. The patient had minimal discomfort, even at dressing changes.



Ferris Mfg. Corp.

5133 Northeast Parkway

Fort Worth, TX 76106 USA

Phone: 1-800-POLYMEM (765-9636), +1 630-887-9797

Email: info@FerrisPolyMem.com

Web site: www.PolyMem.com

BIBLIOGRAPHY

1. Bergstrom N, Horn SD, Smout RJ, et al. The national pressure ulcer long-term care study: outcomes of pressure ulcer treatments in long-term care. *J Am Geriatr Soc.* 2005;53(10):1721-1729. 2. Driver VR. Silver dressings in clinical practice. *Ostomy Wound Manage.* 2004 Sep;50(9A Suppl):11S-15S. 3. Fluhr JW, Gloor M, Lehmann L, Lazzerini S, Distante F, Berardesca E. Glycerol accelerates recovery of barrier function in vivo. *Acta Derm Venereol.* 1999;79:418-421. 4. Worley CA. So, what do I put on this wound? Making sense of the wound dressing puzzle: Part II. *Dermatol Nurs.* 2005;17(3):203-205. 5. Hess CT. *Wound Care Clinical Guide.* Lippincott Williams & Wilkins, Ambler, PA. 2005; 275-281. 6. Fowler E, Papen JC. Clinical evaluation of a polymeric membrane dressing in the treatment of dermal ulcers. *Ostomy/Wound Manage.* 1991;35:35-38,40-4. 7. Beitz AJ, Newman A, Kahn AR, Ruggles T, Eikmeier L. A polymeric membrane dressing with antinociceptive properties: analysis with a rodent model of stab wound secondary hyperalgesia. *J Pain.* 2004 Feb;5(1):38-47. 8. Yastrub DJ. Relationship between type of treatment and degree of wound healing among institutionalized geriatric patients with stage II pressure ulcers. *Care Manag J.* 2004 Winter;5(4):213-8.

ORIGINAL POSTER PRESENTED AT*:

10th Anniversary EPUAP Open Meeting. Poster #20.
August 30 - September 1, 2007. Oxford, England.

18th Conference of the European Wound Management Association. Poster #P36.
May 14 - 16, 2008. Lisbon, Portugal.

* This version has been modified from the original; it reflects PolyMem branding.

Unless otherwise indicated, all trademarks identified are owned by or licensed to Ferris. © 2013, Ferris Mfg. Corp., 5133 Northeast Parkway, Fort Worth, TX 76106 USA
MKL-336, REV-1, 0213